ISSN: 2707-1146
e-ISSN: 2709-4189

DOI: https://doi.org/10.36719/2707-1146/43/9-19

Ilqar Hasanov
"Ozon" Medical Center, Ganja
Doctor of Science in Medicine
ihasanov61@gmail.com
Aygun Aliyarbayova
Azerbaijan Medical University
Doctor of Philosophy in Medicine
aeliyarbeyova@amu.edu.az

EXPERIMENTAL STUDY OF CHANGES IN MORPHOLOGICAL PECULIARITIES OF THE EOSINOPHILIC LEUKOCYTE IN THE LUNG UNDER THE INFLUENCE OF THE MACROPHAGE MIGRATION INHIBITOR FACTOR

Abstract

The research investigated on observation of eosinophilic leukocytes in the lungs of white laboratory rats under the effect of a Macrophage migration inhibition factor (MIF) by light and electron microscopy. The object of the study was 60 white male rats subdivided into 3 groups: control, placebo (saline injection), and main (MIF injection). The eosinophilic leukocytes are detected by specific cytoplasmic eosinophilic granules and ultrastructurally visible distinctive osmiophilic granules. The subpopulations of indicated cells in the lungs were identified as "stromal-interstitial", within "BALT", "perivascular" and "bronchial". It was found that in the experiment, the administration of MIF induces the migration of eosinophilic leukocytes into the alveoli and respiratory tract. It is necessary to note that the introduction of MIF has a gradual effect on the quantification and functional activity of eosinophilic leukocytes in the lungs of laboratory white rats: an increase in the first 2-7 days and stabilization at a higher level in the next 15-30 days. At least two ways of the effect of MIF on eosinophilic leukocytes have been evaluated: 1) by direct reception of MIF and 2) by indirect mechanisms. After injection of MIF, eosinophilic leukocytes probably have a regulatory effect in various microzones of the lung. The obtained results show that research in this direction may be promising in modeling immunopathological lung diseases.

Keywords: *eosinophilic leukocytes, MIF, morphology, lungs*

Introduction

The "Macrophage migration inhibition factor" (MIF) refers to proinflammatory cytokines (Song, Xiao, Dekker, Poelarends, Melgert, 2022: 105; Kong, Chen, Lan, 2022: 4908). As well as in recent years has been widely studied its significance role in acute and chronic inflammation (Shen, Tang, Zhu, Huang, 2021: 6; Du, Hao, Ma, Liu, 2022:01; Wen, Zhu, Zhang, Yang, Gao, Li, Yang, Liu, Tang, 2022: 01), sepsis (Toldi, Nemeth, Hegyi, Molnar, Solymar, Farkas, Alizadeh, Rumbus, Pakai, Garami, 2021: 8051), shock (Patel, Yamada, Oliveira, Stiehler, Zechendorf, Hinkelmann, Kraemer, Stoppe, Collino, Collotta, Ferreira, Pillmann, Sordi, Marzi, Relja, Marx, Martin, Thiemermann, 2022: 11), autoimmune (Bilsborrow, Doherty, Tilstam, Bucala, 2019: 1) and oncological pathologies (Charan, Das, Mishra, Chatterjee, Varikuti, Kaul, Misri, Ahirwar, Satoskar, Ganju, 2020: 1; Noe, Mitchell, 2020:1). The anti-glucocorticoid effects of the MIF have already been proven (Fan, Kao, Yang, Gu, Harris, Fingerle-Rowson, Bucala, Ngo, Beaulieu, Morand, 2014: 2059).

There are some explorations on its role in angiogenesis, carcinogenesis, and tissue regeneration (Zhang, Zhu, He, Fan, Deng, Hong, Liang, Zhao, Li, Zhang, 2019: 12641). The peculiarities of MIF expression have been studied in kidneys, skin, pituitary gland, etc. organs, as well as alteration caused by MIF injection (Li, Tang, Lv, Wang, Yang, Tang, Huang, He, Zhou, Huang, Klug, Meinhardt, Fingerle-Rowson, Xu, Zheng, Lan, 2019: 3867; Ding, Li, Wu, Lv, Yu, Hao, 2022: 18558; Shimizu, 2005: 65).

The target of MIF is macrophages (neutrophilic leukocytes), macrophages, dendritic cells of lymphoid clusters and nodes, microglial cells (glial macrophages), plasma cells, tissue basophils, some populations of lymphocytes, as well as smooth muscles, fibroblastic line cells, endothelium, covering and glandular epithelial cells (Calandra, Roger, 2003: 791).

The changes caused by MIF in the lungs are still poorly understood, although it is supposed that it has a pathogenetic role in bronchial asthma and obstructive pulmonary diseases (Rossi, Haslett, Hirani, Greening, Rahman, Metz, Bucala, Donnelly, 1998: 2869; Florez-Sampedro, Soto-Gamez, Poelarends, Melgert, 2020: L1184). One of the targets of the action of MIF may be eosinophilic leukocytes located in different organs (Rosenberg, Dyer, Foster, 2013: 9). MIF may be important in the pathogenesis of allergic diseases and helminthiasis, affecting the differentiation, functional activity and migration of eosinophilic leukocytes; the participation of eosinophilic leukocytes in this process has also been determined (Bozza, Lintomen, Kitoko, Paiva, Olsen, 2020: 15).

The results of numerous studies in clinical conditions are contradictory about the population of eosinophilic leukocytes in the lungs, as well as in experiments (Kowalski, Weller, 2016: 607-617; Blanchard, Rotenberg, 2009: 81-121).

The analysis shows that the topography, light microscopic, and ultrastructural features of eosinophilic leukocytes of the lungs are insufficiently systematized (23, 24). Thus, the following aspects of the morphology of these cells in the lungs are currently superficially studied:

- Appropriate his topography, frequency of occurrence, and morphometric indicators;
- Topographic, density-quantitative, and morphological changes in eosinophilic leukocytes that may be caused by the introduction of MIF;
- The direction, severity, and dynamics of changes in the population of eosinophilic leukocytes in the post-injection period of MIF.

The aim of the study.

The purpose of this research was a comprehensive study of the morphological features of eosinophilic leukocytes in the lungs of white laboratory rats in norm and after intravenous administration of MIF.

Materials and methods of research.

The investigation was conducted on 60 adult male white rats of an unknown breeding line, physically active, weighing between 200 and 250 g. The experimental animals acquired from the Scientific Research Center of Azerbaijan Medical University were kept in standard vivarium conditions, as well as with approved health certificates. The Macrophage Migration Inhibitor factor (MIF Rat, ProSpec (Protein-Specialists) CYT-193) was obtained from ProSpec-Tany TechnoGene Ltd. (Ness-Ziona, Israel) and dissolved in saline solution. The experimental animals were divided into 3 following groups: 1) 12 rats served as the control group, without any intervention; 2) 12 rats serving as compared group (placebo), were once receiving an intravascular injection of 0.3ml saline; 3) 36 rats served as the main experimental group, were receiving also the once intravascular injection of MIF diluted in saline solution (1.39µg MIF dissolved in 0.3ml saline). At 2 hours, 2 days, 3 days, 7 days, 15 days, and 30 days post injection (both saline and MIF), the animals were decapitated under anesthesia and excluded from the experiment. The investigated tissue samples were taken from the right (4 pieces from each lobe) and left (around the portal and peripheral zone) lungs (Fig.1).

During the experiments were followed the principles of the declaration of the European Union on animals used for experimental and other scientific purposes (Guidelines for accommodation and care of animals (article 5 of the convention) approved by the multilateral consultation, 2006: cons. 123).

The samples were placed in 4.0% buffered formalin for histopathological examination, then embedded in paraffin, while for electron-microscopic analysis fixed in buffered 2.5% glutaraldehyde + 2% paraformaldehyde + 4% glucose + 0.1% picric acid solution and embedded in Araldite- Epon mixture. The obtained semithin sections from Araldite-epon blocks in thickness 0.5-1.0µm were stained with double polychromatophil staining (solution "A" - 0.5% methylene blue,

ISSN: 2707-1146
e-ISSN: 2709-4189

0.5% azur-II, 0.5% bura, and solution"B" - 5% alcohol, 0.1% alkaline fuchsin) (D'Amico, 2005: 207), as well as the 3-5µm sections purchased from paraffin blocks stained with hematoxylin and eosin. Studies at the light-optical level were carried out in stereometric mode under an Axio Scope A14 (Carl Zeiss) microscope with an Axiocam ERc5s video camera.

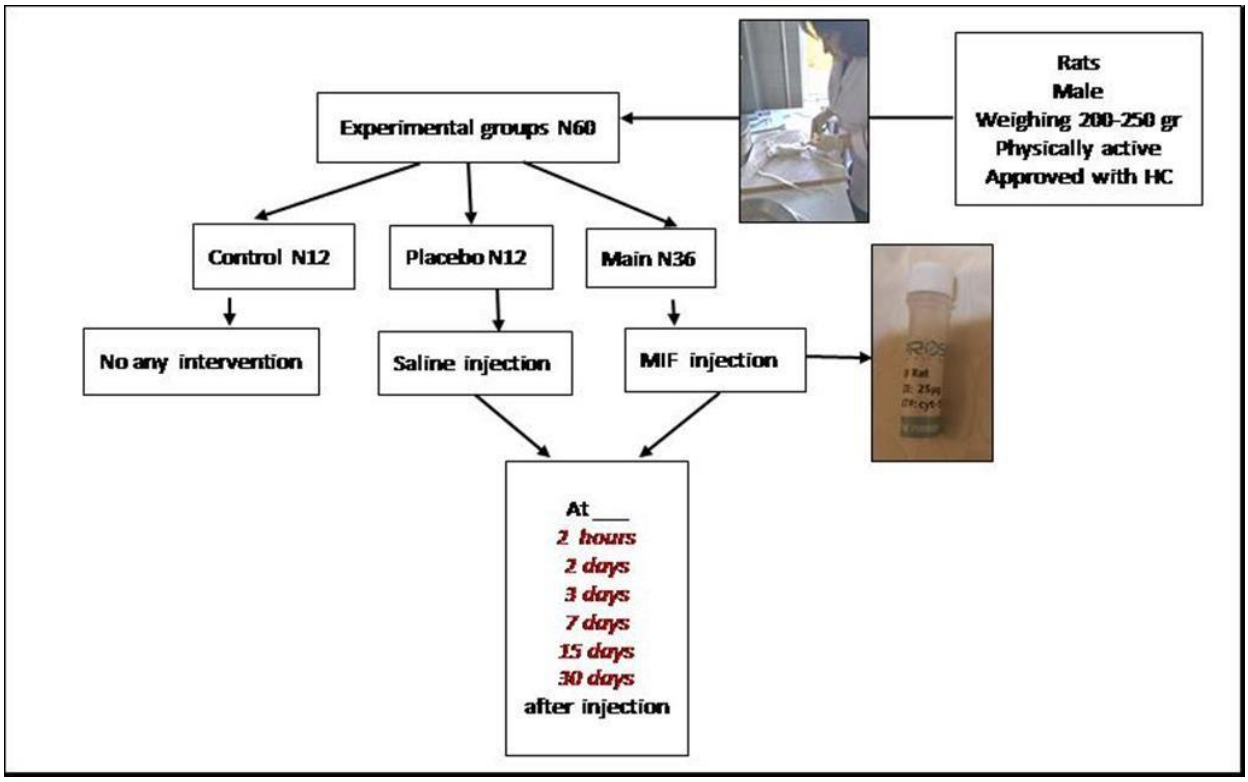

Figure 1. Experimental protocol of research work where male rats administered by saline, MIF, and animals were excluded from the experiment at various times, as well as the obtained information, was compared by data of control group rats.

After examination of the semithin section, the interested areas of the Araldite-Epon blocks were pointed for studying under TEM – transmission electron microscope (JEM-1400, Japan). Gained from the same blocks ultrathin sections 50-60 nm thick were first stained with 2.0% uranyl-acetate, then with 0.6% pure lead-citrate prepared in a 0.1N solution of NaOH and were analyzed at a voltage of 80.0 kV on TEM.

During conducting the experiments and interpreting their results were used to appropriate and methodological recommendations (Rosenberg, Dyer, Foster, 2013: 9 and 23, 24). Also, the morphometric analysis of objects was performed.

The average mathematical value of quantitative indicators and its average error (M ± m) were calculated, and the statistical reliability of differences at the accuracy level P=0.95 ($p<0.05$) was evaluated by the t-criterion (27). The p_1 is determined in comparison with the norm, and p_2 is compared with the placebo group (injections of saline solution).

Research results and their discussion.

In control white rats, eosinophilic leukocytes were found in the stroma of the lung, especially in the portal region (root, hilium); along the neurovascular bundles in the fibrotic tissue line; in the stromal septa of various zones; around microvessels; in bronchus-associated lymphoid tissue (BALT); in the wall of medium and large diameter bronchi. They are not found in the bottom of the alveoli, and in small bronchi, they are observed individually.

As seen in Fig. 2, a diagram that shows the distribution of the eosinophilic leukocyte population in the lungs of the control white rat, depending on the histological location and counted the percentage of eosinophil quantification.

ISSN: 2707-1146
e-ISSN: 2709-4189

The stromal-interstitial eosinophilic leukocytes presented is 31,4%; around and within the wall of vessels known as perivascular is 26,2%; within BALT is 22,1%; in the wall and around of bronchi named as bronchial is 20,3%.

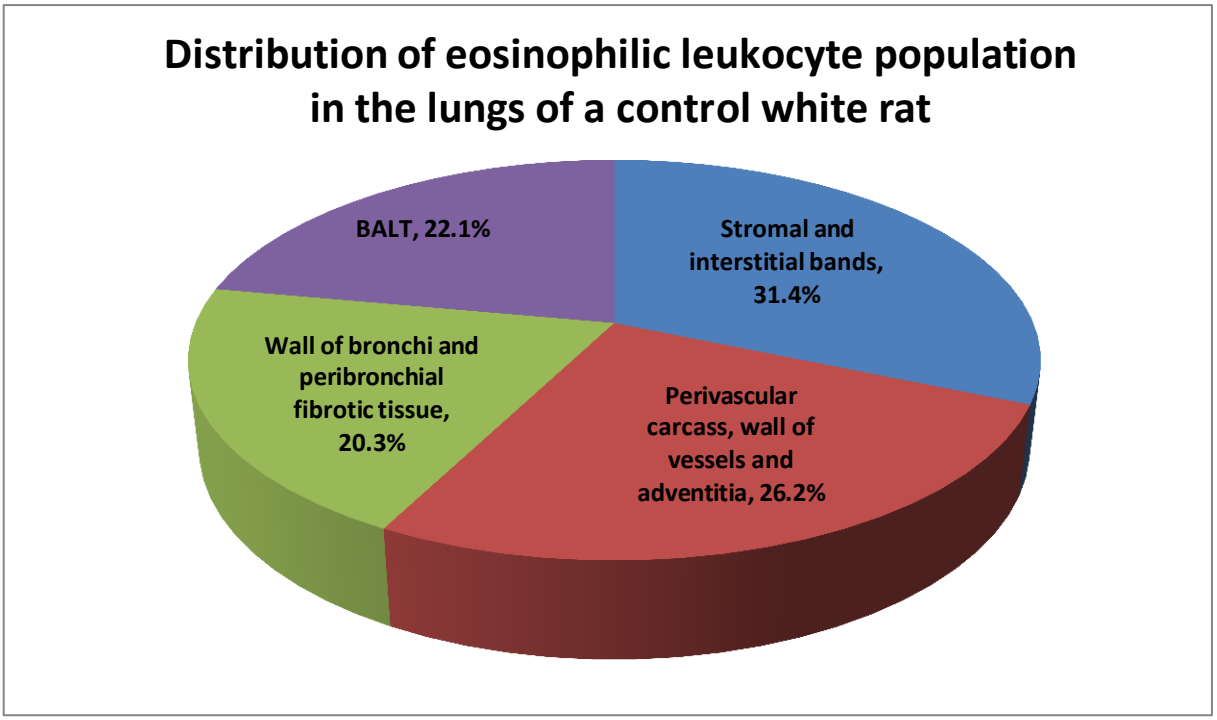

Figure 2. Distribution of eosinophilic leukocyte population in the lungs of a control white rat.

The main criterion for determining eosinophilic leukocytes at the light-optical level was accepted the localization of an eosinophilic substrate with cytoplasmic aggregates in cells as a granular or grossly diffuse nature.

However, the eosinophilic structures observed in the lumen of the bronchi, and sometimes in the bottom of alveoli, were evaluated as "degenerative eosinophilic leukocytes" and "degenerative eosinophilic corpuscles", which is quite consistent with the generally accepted approach (Erjefält, Persson, 2000: 2074, and 23, 24).

During electron microscopic analysis, the specific ultrastructural characteristic element determining of eosinophilic leukocytes were taken as the electron-dense osmiophilic granules, however along with them were also taken into account the general shape of these cells, the shape of the nucleus, the composition of cytoplasmic organelles, the presence of residual bodies and manifestations of exocytosis (degranulation, extrusion) (Muniz, Weller, Neves, 2012: 281-288; Klion, Ackerman, Bochner, 2020: 179 and 24).

On light and electron microscopic examination (Fig.3) eosinophils located in different regions of lungs singly or in groups of 2-3 cells and detected by their nuclear shape and eosinophilic granules presenting in cytoplasm. The eosinophilic leukocytes are 9.0-13.6 µm wide (11.2±0.8 µm), irregularly contoured, sometimes with 1-2 cytopodia of 0.4-1.0 µm (visible on electronogram in Fig.3B, C, D), they have only of simple support type connections with surrounding cells.

ISSN: 2707-1146
e-ISSN: 2709-4189

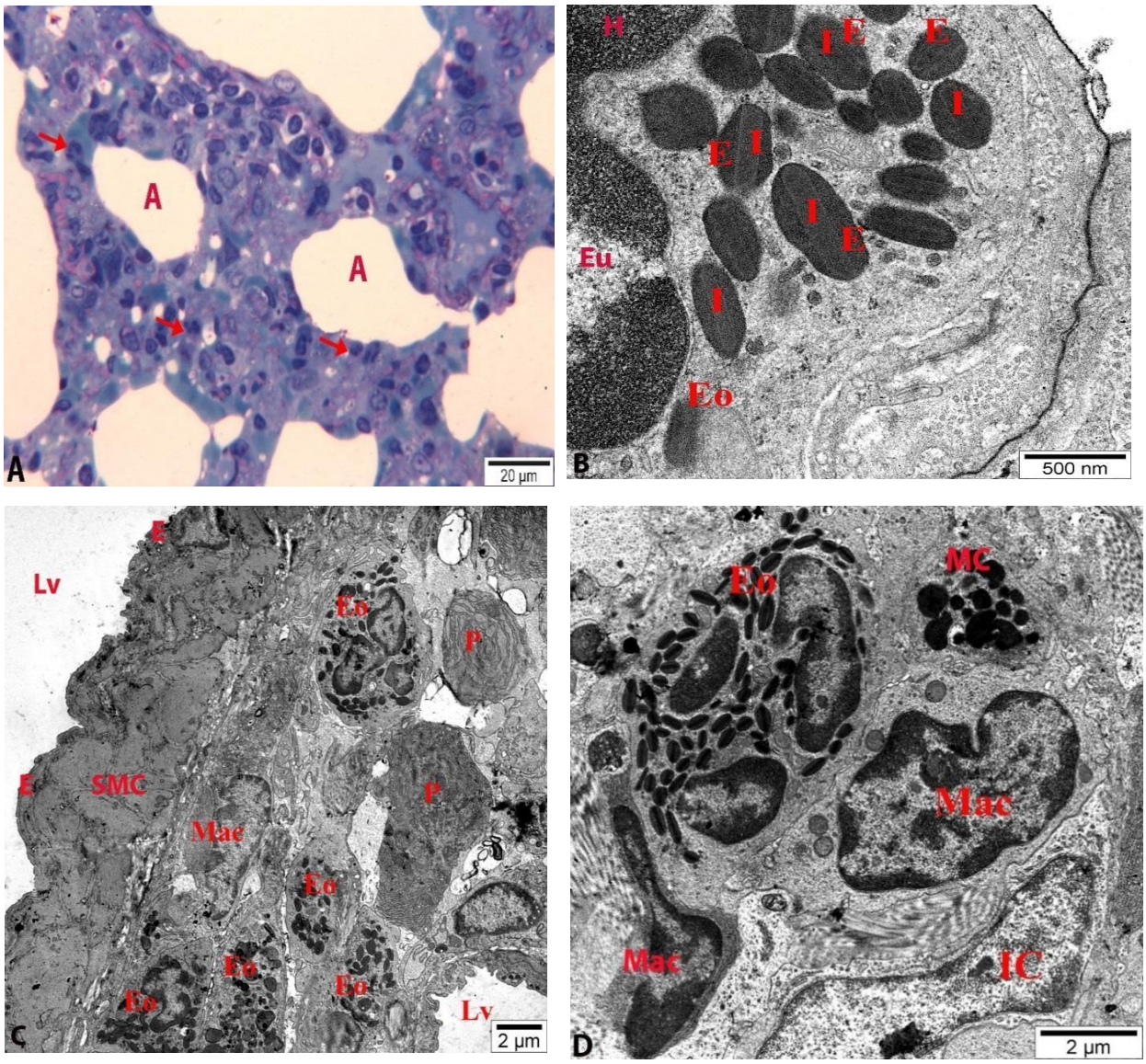

Figure 3. Microscopic presentation of eosinophilic leukocytes of intact white laboratory rats. A – localization within the interstisial stroma (shown by red arrow), between alveoli (indicated by A); B – characteristic eosinophilic cytoplasmic osmiophilic granules in oblong shaped, containing enzymes arranged in internum (I) and externum (E), accumulation of heterochromatin (H) and euchromatin (Eu) in nucleus; C – eosinophils situated in groups within tunica adventitia of the arterial vessel (Lv-lumen of vessels, SMC-smooth muscle cells, E-endothelial cells) and contacts with some connective tissue cells (Mac-macrophages, P-plasma cells), d – interaction of eosinophils within stroma with connective tissue cells (MC-mast cells, IC-interstitial cell). A – semithin section, double polychromatophil staining, scale bar 20µm; B–D - ultrathin section, uranyl acetate and pure lead citrate staining, scale bars B-500nm, C, D -2µm.

Under electron microscope observed more simple support and tight junction between them, but direct fixation contacts are not determined (Fig.3C). We consider that the absence of such contacts is important in the displacements of those cells between vessel and tissue, also within tissue, as well as in the performance of specific functions of them.

Eosinophilic leukocytes were not found in the floor of alveoli and bronchioles in intact white rats, which may indicate that mentioned cells does not freely migrate into the airways due to the

ISSN: 2707-1146
e-ISSN: 2709-4189

absence of relevant inducers and pathogenic factors. No significant difference was noted in the incidence of eosinophilic leukocytes in the right and left lungs.

Ultrastructurally, on Fig. 3B showed eosinophilic leukocytes in the lungs have eu- and heterochromatin (indicated by Eu and H) accumulations in the nucleus, as well as clearly visible synthesis and secretion microsystems in the cytoplasm, specific osmiophilic granules, primary and secondary lysosomes, sparsely scattered cytoskeletal elements; the specific osmiophilic granules with oblong shape contain crystal like electron dense center internum (shown in fig by I) surrounding by less electron dense externum (marked in fig by E). Around of the tunica adventitia of arterial vessels (Fig.3C) placed the different cells, such as eosinophils, macrophages, plasma cells. The former cells are distinguished from the neighbour cells by their nuclear shape, cytoplasmic spesific granules and different electron-optical density. On Fig.3D demonstrated interaction of eosinophils with macrophages, mast cells, interstisial cells within interstisium of lung.

The administration of MIF did not significantly change the localization of the studied cells in the lungs. Compared with control (p_1>0.05) and placebo (p_2>0.05) groups, the number of eosinophilic leukocytes were unreliable increased at 2 hours after injection of MIF. However, during the experiment, the total population and relative numbers of livestock showed continuous growth, and then stabilization at a higher level. So, compared with control the increase in the number of eosinophilic leukocytes was 3.3% 2 hours after the injection of MIF, 28.4% after 2 days, 24.4% after 3 days, 18.5% after 7 days, 12.6% after 15 days, and 7.4% after 30 days. The introduction of saline solution had no significant effecton animals of the placebo group, therefore, compared with the control, the increase in the number of corresponding cells was only 0.1-0.5% (Fig. 4).

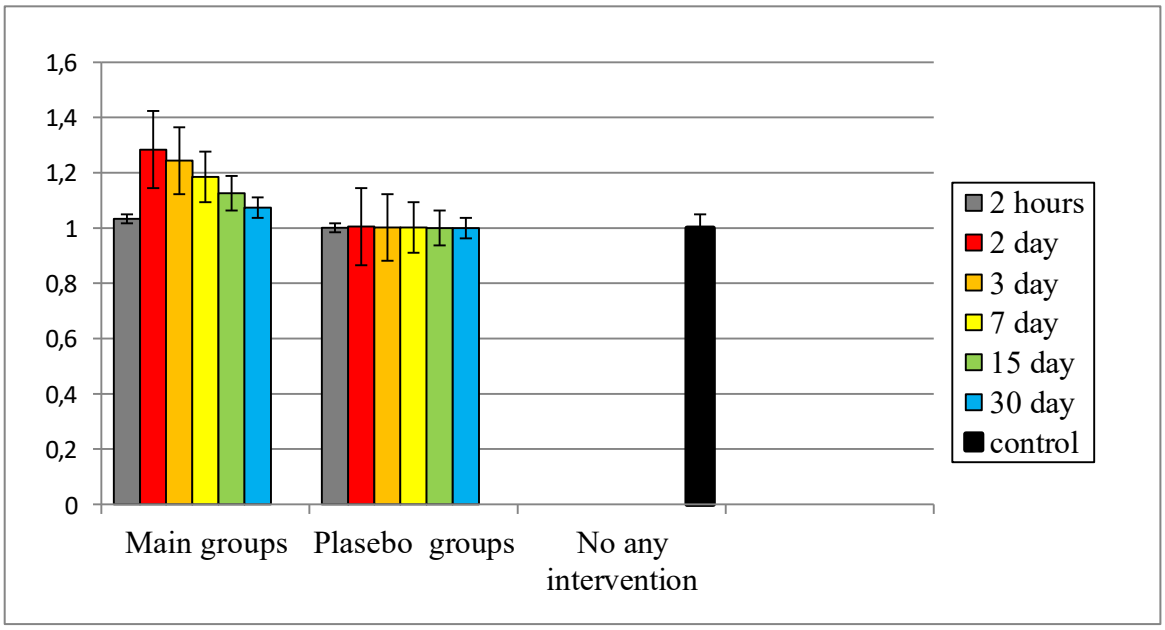

Figure 4. Dynamics of changes on quantification of eosinophils in lung tissue sections of white laboratory rats (in arbitrary units; a.u.). On diagram compared the data of eosinophils of rats that intravenously administred with MIF in main groups (the data of indicated cells shown with different color related to time of experiment), a saline solution in placebo groups, as well as the data of animals in control group, which hadn't done any intervention.

In conclusion, we note that during the experiment - on the 2nd, 3rd and 7th days after the injection of MIF - the total number of eosinophilic leukocytes elevated significantly (p_1<0.03 and p_2<0.05). For the further, on the 15th-30th day administration of MIF, the initially detected elevation is replaced by relative stabilization.

ISSN: 2707-1146
e-ISSN: 2709-4189

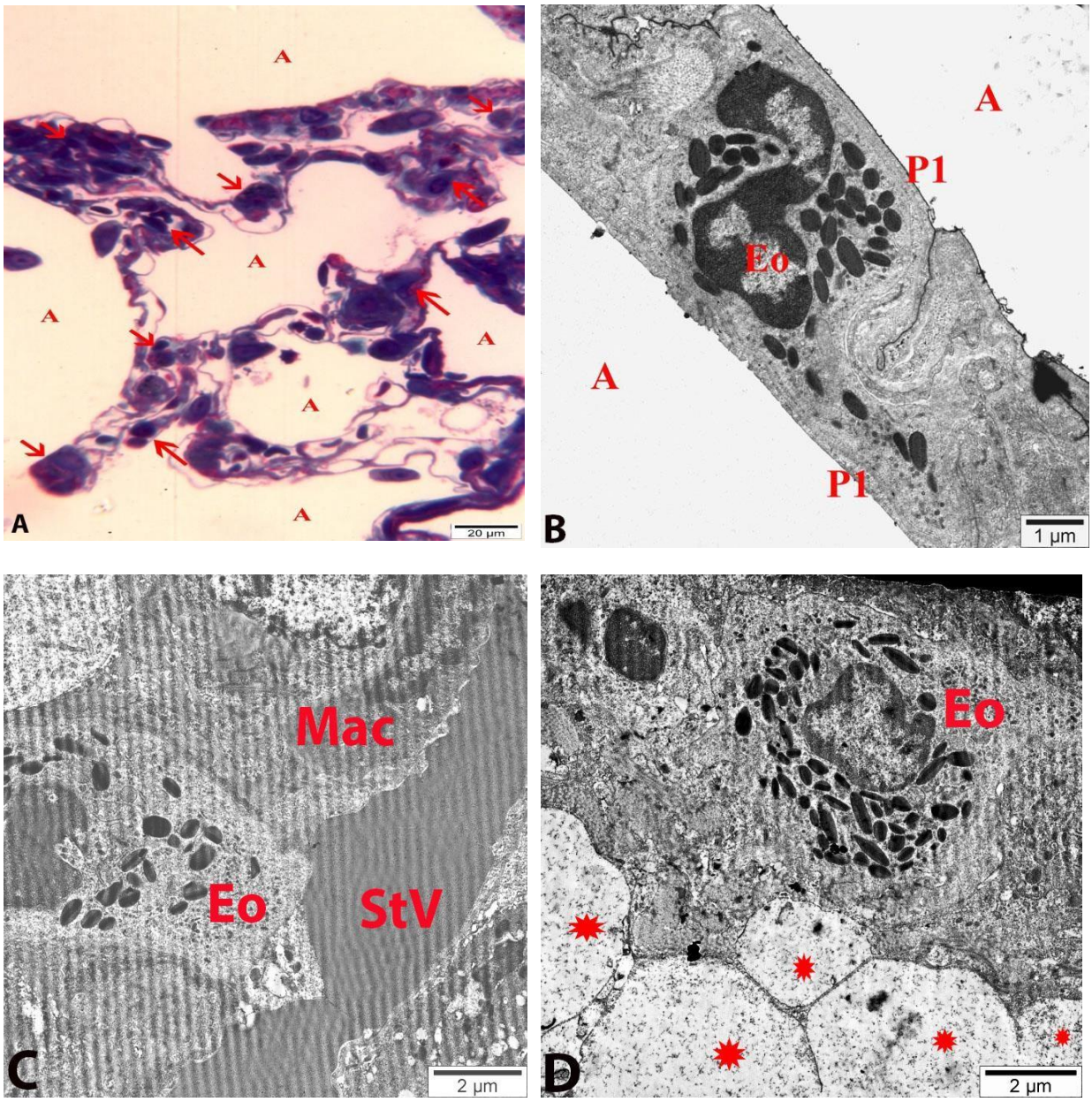

Figure 5. – Topographic features of eosinophil leukocytes in the lungs on days 2-3 after MIF injection. A – migration eosinophils (shown by red arrow) to the alveolar lumen (marked by A) and bottom on 2nd day; B – localization in the aero-hematic barrier on 2nd day (P1-pneumocyte 1, A-alveoli,); C – close contact with a stagnant microvessel (indicated by StV) and macrophages (Mac) on 3rd day; D – localization in the edematous interstitium (indicated by red star) on 3rd day. A – semithin section, double polychromatophil staining, scale bar 20µm; B–D - ultrathin section, uranyl acetate and pure lead citrate staining, scale bars B-1µm, C, D -2µm.

In parallel, eosinophilic leukocytes were observed around the alveoli, in the aerohematic barrier and in the bottom of the alveoli, which was not typical for the control and placebo groups. During this period (2-7 days after injection), the analyzed cells were found around the alveoli, in the aerohematic barrier, on the alveolar floor and in the lumen of the alveoli. Especially on the 2nd and 3rd days, eosinophilic leukocytes are located very close to stagnant, closed microvessels with degenerated endothelial cells, and microfields of perivasal plasmorrhage or form contacts with such microvessels (Figure 5).

ISSN: 2707-1146
e-ISSN: 2709-4189

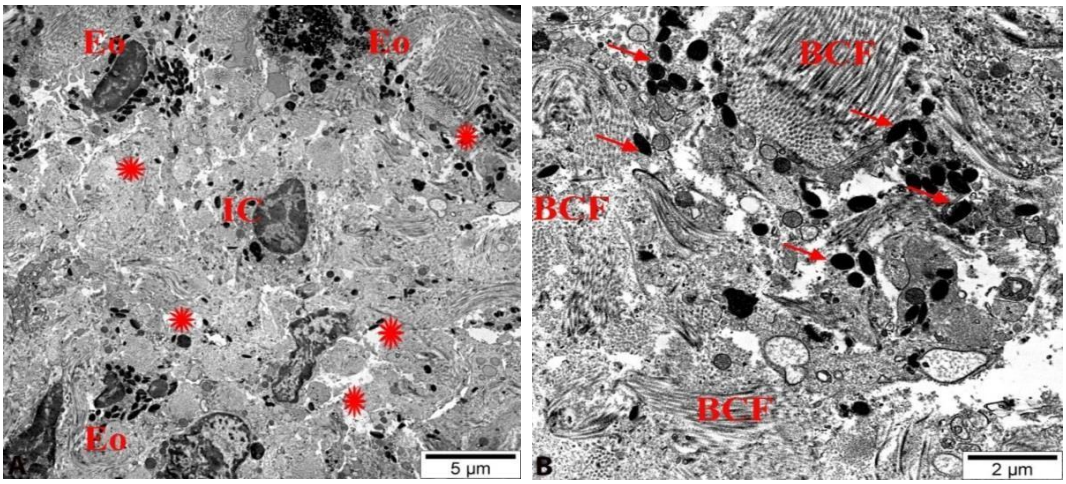

Figure 6. – Exocytosis (degranulation, extrusion) of specific osmiophilic granules from eosinophilic leukocytes. A – day 7 after MIF injection; B – day 30 after MIF injection; specific granules (shown byred arrow) between interstitial cells (IC), within edematous tissue (marked by red stars) and bundle of collagen fibers (BCF), background of fibrosis. Ultrathin section, uranyl acetate and pure lead citrate staining, scale bars shown on electronograms.

During the experiment, from the 2nd hour to the 15th day after injection were monitored the ultrastructural manifestations of extrusion of specific osmophilic granules and lysosomal exocytosis of eosinophilic leukocytes in the lungs. This is especially evident on the 7th-15th day within fibrous tissue around the small bronchi, in interstitial areas near to increased fibrous strands (Figure 6). It should be noted that there are no sources in the literature on extrusion and lysosomal exocytosis of these cells under the influence of MIF. However, as not yet been found the systematic information on the functional determination of these processes and their role in inflammation, fibrosis caused by injection of MIF into the lungs, but our research in this direction continues.

On the 15th and 30th days after the injection of MIF the eosinophilic leukocytes migrated between collagen bundles within stroma and in the peribronchial regions, where specific osmophilic granules are extruded, which is not typical for the group of control and placebo groups (injection of saline solution) (Figure 6).

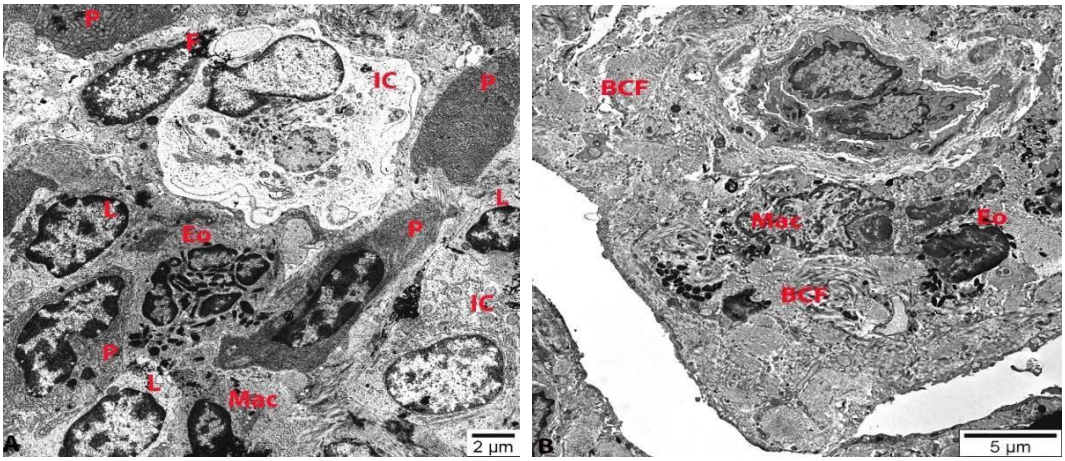

Figure 7. – An electronogram presented the cooperation of immune-competent cells within the stroma of lung tissue after administration of MIF. Relatively numerous contacts between eosinophilic leukocytes (Eo) and macrophages (Mac), lymphocytes (L), plasma cells (P), interstitial and fibroblasts (F). A – 3rd day after MIF injection; B – Day 7 after MIF injection. On the 7th day after injection clearly visible bundles of collagen fibers (BCF) around congested vessels and cells. Ultrathin section, uranyl acetate, and pure lead citrate staining, scale bars shown on electronograms.

It is possible that eosinophilic leukocytes induce fibrosis in stroma due to the extrusion of biologically active substances with a paracrine effect, but it is necessary to investigate in general the possible physiological/pathophysiological effects of exocytosis (extrusion) of specific granules of eosinophilic leukocytes.

After the injection of MIF condensed the cell complexes formed by eosinophilic leukocytes with lymphocytes, macrophages, tissue basophils, and perivasal adventitial cells, and also increased the frequency of simple and specialized contacts between cells. We evaluated this feature as "cooperation of eosinophilic leukocytes with other immunocompetent cells" (Figure 7.).

The dynamics of "increase-stabilization" is also observed in the number of immunocompetent cells, including eosinophilic leukocytes: first an increase (2-7 days), and then a relative stabilization (15-30 days).

In clusters of formed elements, which are sometimes observed in the lumen of blood vessels, were not detected eosinophilic leukocytes in any of the experimental groups, although these cells were found, as a rule, around small and medium-diameter vessels in various segments of the samples of lungs.

Thus, it can be considered that the introduction of MIF causes quantitative changes in the population of eosinophilic leukocytes in the lungs (increase and subsequent stabilization). At the same time, we determined the light microscopic and ultrastructural manifestations of changes in the functional activity of the studied cells. Presumably, this effect is realized in at least two ways: 1) Direct effect on "target" cells based on the direct reception of MIF in eosinophilic leukocytes. Considering the information that eosinophilic leukocytes have such MIF receptors as CD74 and CXCR4 (M. Bozza et al, 2020: 15), the probability of such an effect is high. 2) The effect of MIF injection on eosinophilic leukocytes through indirect mechanisms. We believe that intermediate rings, i.e. specialized lymphocytes, tissue basophils, activated macrophages, as well as fibroblast cells, are also involved in this mechanism; we have discovered that the signs of this may be polymorphism and violation in the number of cooperative cell complexes, including eosinophils.

As shown by some authors (Akuthota, Weller, 2012: 113-119; Rosenberg et al., 2013: 9-22), the results of the current study prove the prospects of a comprehensive study of eosinophilic leukocytes in the analysis of the prognosis, pathogenesis, clinical course of the lung disease related to its inflammation, fibrotic-obstructive and cancers.

Conclusion

1. The total population of eosinophilic leukocytes in the lungs of intact white laboratory rats consists of at least 4 distinct subpopulations: 1) "stromal interstitial", 2) within "BALT", 3) "perivascular" and 4) "bronchial".
2. In the experiment, the introduction of MIF stimulates eosinophilic leukocytes of the lungs.
3. During the experiment, the administration of MIF induces (accelerates) the migration of eosinophilic leukocytes into the alveoli and in the lumen of the respiratory tract.
4. Eosinophilic leukocytes interact with tissue basophils, macrophages, specific dendritic cells and certain types of lymphocytes on 2nd-7th days after the injection of MIF, also with myocytes and adventitial cells on 2nd-3rd days, and demonstrated intensive functional cooperation on 7th - 15th days with fibroblastic cells, which is manifested by an increase in the number of corresponding cellular contacts, elevated level of morphological polymorphism and the high extrusion rate of specific osmophilic granules.

References

1. Song, S., Xiao, Z., Dekker, F.J., Poelarends, G.J., Melgert, B.N. (2022). Macrophage migration inhibitory factor family proteins are multitasking cytokines in tissue injury. Cell Mol.LifeSci. 79(2), 105 p. doi: 10.1007/s00018-021-04038-8.
2. Kong, Y.Z., Chen, Q., Lan, H.Y. (2022). Macrophage Migration Inhibitory Factor (MIF) as a Stress Molecule in Renal Inflammation. Int. J. Mol. Sci. April 28; 23(9):4908. doi: 10.3390/ijms23094908.

3. Shen, D., Tang, C., Zhu, S., Huang, G. (2021). Macrophage migration inhibitory factor is an early marker of severe acute pancreatitis based on the revised Atlanta classification. BMC Gastroenterol 21(1):34. doi: 10.1186/s12876-020-01598-0.
4. Du, Y., Hao, H., Ma, H., Liu, H. (2022). Macrophage migration inhibitory factor in acute kidney injury. Front Physiol., Sep, 2:13:945827.doi: 10.3389/fphys.2022.945827
5. Wen, Y., Zhu, Y., Zhang, C., Yang, X., Gao, Y., Li, M., Yang, H., Liu, T., Tang, H. (2022). Chronic inflammation, cancer development and immunotherapy. Front. Pharmacol. Oct 14:13:1040163. doi: 10.3389/fphar.2022.1040163.
6. Toldi, J., Nemeth, D., Hegyi, P., Molnar, Z., Solymar, M., Farkas, N., Alizadeh, H., Rumbus, Z., Pakai, E., Garami, A. (2021). Macrophage Migration Inhibitory Factor as a Diagnostic and Predictive Biomarker in Sepsis: Meta-Analysis of Clinical Trials. Sci. Rep. 11:8051. doi: 10.1038/s41598-021-87613-0.
7. Patel, N.M., Yamada, N., Oliveira, F.R.M.B., Stiehler, L., Zechendorf, E., Hinkelmann, D., Kraemer, S., Stoppe, C., Collino, M., Collotta, D., Ferreira, G. A., Pillmann, H.R., Sordi, R., Marzi, I., Relja, B., Marx, G., Martin, L., Thiemermann, C. (2022). Inhibition of macrophage migration inhibitory factor activity attenuates haemorrhagic shock-induced multiple organ dysfunction in rats. Front Immunol, 13:886421. doi: 10.3389/fimmu.2022.886421.
8. Bilsborrow, J.B., Doherty, E., Tilstam, P.V., Bucala, R. (2019). Macrophage migration inhibitory factor (MIF) as a therapeutic target for rheumatoid arthritis and systemic lupus erythematosus. Expert OpinTher Targets. September; 23(9), pp.733-744. doi:10.1080/14728222.2019.1656718
9. Charan, M, Das, S, Mishra, S, Chatterjee, N, Varikuti, S, Kaul, K, Misri, S., Ahirwar, D.K., Satoskar, A.R., Ganju, R.K. (2020). Macrophage migration inhibitory factor inhibition as a novel therapeutic approach against triple-negative breast cancer. Cell Death Dis; 11(9), 774 p. doi 10.1038/s41419-020-02992-y.
10. Noe, J.T., Mitchell, R.A. (2020). MIF-Dependent Control of Tumor Immunity. Front. Immunol. 25 November. Sec. Cancer Immunity and Immunotherapy, Volume 11. https://doi.org/10.3389/fimmu.2020.609948
11. Fan, H., Kao, W., Yang, Y.H., Gu, R., Harris, J., Fingerle-Rowson, G., Bucala, R., Ngo, D., Beaulieu, E., Morand, E.F. (2014). Macrophage migration inhibitory factor inhibits the antiinflammatory effects of glucocorticoids via glucocorticoid-induced leucine zipper. ArthritisRheumatol. 66, pp.2059-2070. doi: 10.1002/art.38689.
12. Zhang, Y., Zhu, W., He, H., Fan, B., Deng, R., Hong, Y., Liang, X., Zhao, H., Li, X., Zhang, F. (2019). Macrophage migration inhibitory factor rejuvenates aged human mesenchymal stem cells and improves myocardial repair. Aging (Albany NY) Dec 27; 11(24), pp.12641-12660. doi: 10.18632/aging.102592.
13. Li, J.H., Tang, Y., Lv, J., Wang, X.H., Yang, H., Tang, P.M.K., Huang, X.R., He, Z.J., Zhou, Z.J., Huang, Q.Y., Klug, J., Meinhardt, A., Fingerle-Rowson, G., Xu, A.P., Zheng, Z.H., Lan, H.Y. (2019). Macrophage Migration Inhibitory Factor Promotes Renal Injury Induced by Ischemic Reperfusion. J. Cell. Mol. Med. 23 (6), pp.3867-3877. 10.1111/jcmm.14234.
14. Ding, N., Li, P.L., Wu, K.L., Lv, T.G., Yu, W.L., Hao, J. (2022). Macrophage migration inhibitory factor levels are associated with disease activity and possible complications in membranous nephropathy. Sci Rep. Nov. 3;12(1):18558. doi: 10.1038/s41598-022-23440-1.
15. Shimizu, T. (2005). Role of macrophage migration inhibitory factor (MIF) in the skin. J. Dermatol. Sci., vol. 37(2), pp.65-73. doi: 10.1016/j.jdermsci.2004.08.007.
16. Calandra, T., Roger, T. (2003). Macrophage migration inhibitory factor: a regulator of innate immunity. Nature Reviews Immunology,2003; 3(10): 791–800.
17. Rossi, A.G., Haslett, C., Hirani, N.,Greening A.P., Rahman I., Metz C.N., Bucala R., Donnelly C.S. (1998). Human circulating eosinophils secrete macrophage migration inhibitory factor (MIF). Potential role in asthma. J. Clin. Invest.1998 Jun 15; 101(12), pp.2869-2874. doi: 10.1172/JCI1524.

ISSN: 2707-1146
e-ISSN: 2709-4189

18. Florez-Sampedro L., Soto-Gamez A., Poelarends G.J., Melgert B.N. (2020). The role of MIF in chronic lung diseases: looking beyond inflammation. Am. J. Physiol. Lung Cell Mol Physiol, vol. 318(6):L1183-L1197. doi: 10.1152/ajplung.00521.2019.
19. Rosenberg, H., Dyer, K., Foster, P. (2013). Eosinophils: changing perspectives in health and disease. Nat. Rev. Immunol., 2013, vol. 13: 9-22. doi.org/10.1038/nri3341.
20. Bozza, M.T., Lintomen, L., Kitoko, J.Z., Paiva, C.N., Olsen, P.C. (2020). The Role of MIF on Eosinophil Biology and Eosinophilic Inflammation. Clin. Rev. AllergyImmunol., 2020 Feb; 58(1): 15-24. doi: 10.1007/s12016-019-08726-z.
21. Kovalszki, A., Weller P.F. (2016). Eosinophilia. Primary care, 2016, vol. 43,4, pp.607-617. doi:10.1016/j.pop.2016.07.010.
22. Blanchard, C., Rothenberg M.E. (2009). Biology of the eosinophil // Advances in immunology, Vol. 101: 81-121. doi:10.1016/S0065-2776(08)01003-1
23. Oncohema Key Fastest Oncology & Hematology Insight Engine.
24. Anupama Sapkota. (2022). Eosinophils - Definition, Structure, Immunity and Functions, May 3.
25. Guidelines for accommodation and care of animals (article 5 of the convention) approved by the multilateral consultation. Strasbourg. (2006). 15 June cons. 123.
26. D'Amico, F. (2005). A polychromatic staining method for epoxy embedded tissue: a new combination of methylene blue and basic fuchsine for light microscopy. Biotech. Histochem. vol. 80(5–6), pp.207-210.
27. https://medstatistic.ru/index.php
28. Erjefält, J.S., Persson C.G. (2000). New aspects of degranulation and fates of airway mucosal eosinophils. Am. J. Respir. Crit. Care Med., Jun; 161(6): 2074-85. doi: 10.1164/ajrccm.161.6.9906085
29. Muniz, V.S., Weller, P.F., Neves, J.S. (2012). Eosinophil crystalloid granules: structure, function, and beyond . J. Leukoc. Biol., Aug; 92(2), pp.281-288. doi: 10.1189/jlb.0212067.
30. Klion, A.D., Ackerman, S.J., Bochner, B.S. (2020). Contributions of eosinophils to human health and disease. Annu Rev. Pathol. 2020 January 24; 15, pp.179-209. doi:10.1146/annurev-pathmechdis-012419-032756.
31. Akuthota, P., Weller, P.F. (2012) Eosinophils and disease pathogenesis Seminars in hematology, vol. 49,2: 113-119. doi:10.1053/j.seminhematol.2012.01.005.

Received: 03.12.2023 Accepted: 04.04.2024